Mod Rheumatol (2004) 14:160–163
DOI 10.1007/s10165-004-0284-7

CASE REPORT

**Yuko Waguri-Nagaya · Jun Mizutani · Masaaki Kobayashi
Takanobu Otsuka · Nobuo Matsui**

Neuropathic arthropathy caused by chondrosarcoma of the cervical spine

Received: March 6, 2002 / Accepted: November 27, 2003

Abstract We describe a 43-year-old woman with grade 1 chondrosarcoma of the cervical spine who developed neuropathic arthropathy. Plain radiography, computed tomography, and magnetic resonance imaging of the cervical spine revealed a so-called dumbbell tumor. We suggest that this tumor was responsible for the development of neuropathic arthropathy in bilateral hip joints, the left shoulder joint, and the left first metacarpophalangeal joint. This is the first reported case of neuropathic arthropathy secondary to chondrosarcoma of the cervical spine.

Key words Cervical spine · Chondrosarcoma · Neuropathic arthropathy

Introduction

Neuropathic arthropathy occurs following loss of joint sensation. Sensory disturbance can be secondary to a number of diseases, and at least 20 pathological conditions have been reported as causative factors of neuropathic arthropathy.[1] In this article we describe a patient with a cervical spine chondrosarcoma complicated by the development of neuropathic arthropathy.

Case report

In April 1987, a 43-year-old woman could not step forward without experiencing pain in the right buttock. She was initially treated by her family physician and was evaluated by us in May. She had a marked limp due to shortening of the right leg but fairly good range of motion of the hip joint. Hip pain was not a major problem, and she chiefly complained of difficulty with walking. She denied any history of syphilis or a family history of hereditary diseases such as hereditary sensory neuropathy. She had not received steroid medication in any form.

Examination of the heart, lungs, and abdomen was unremarkable. At her first presentation, a small, tender mass was palpable in the anterior portion of the right upper side of her neck. Neurological examination revealed decreased soft touch and pinprick sensation in the right greater trochanteric and shoulder regions. Temperature sensation was documented as normal in these areas. Two-point discrimination was diminished throughout the whole of the upper and lower extremities. Vibratory sensation was slightly diminished in the right greater trochanteric area. Perspiration and histamine flare tests were both normal. The manual muscle test showed all major muscle groups to be good, except for a slight decrease in the right biceps and deltoid muscles. The deep tendon reflex of the right biceps was also diminished. The neurological examination suggested a right C5 radicular lesion and suspected myelopathy at the cervical level. All laboratory examinations, including urinalysis and fasting blood glucose, were within the normal range. The *Treponema pallidum* hemagglutination test was negative.

The first radiographic study of the patient's pelvis was obtained by her family physician in April 1987 (Fig. 1a). It revealed flattening of the right femoral head, joint space narrowing, and reactive osteosclerosis at the load-bearing areas of the right hip. In May 1987, plain radiographs of the right hip showed total disappearance of the femoral head with upward displacement of the greater trochanter and debris in the joint cavity (Fig. 1b). Joint destruction without significant pain suggested neuropathic arthropathy.

Plain radiographs of the cervical spine showed expansion of the right C4–5 intervertebral foramen (Fig. 2). Computed tomography (CT) of the cervical spine demonstrated erosion of the right C4 vertebral body and transverse process

Y. Waguri-Nagaya (✉) · J. Mizutani · M. Kobayashi · T. Otsuka
Department of Musculoskeletal Medicine, Nagoya City University Graduate School of Medical Sciences, Mizuho-ku, Nagoya 467-8601, Japan
Tel. +81-52-853-8236; Fax +81-52-842-0266
e-mail: waguri@med.nagoya-cu.ac.jp

N. Matsui
Nagoya City Rehabilitation Center, Nagoya, Japan

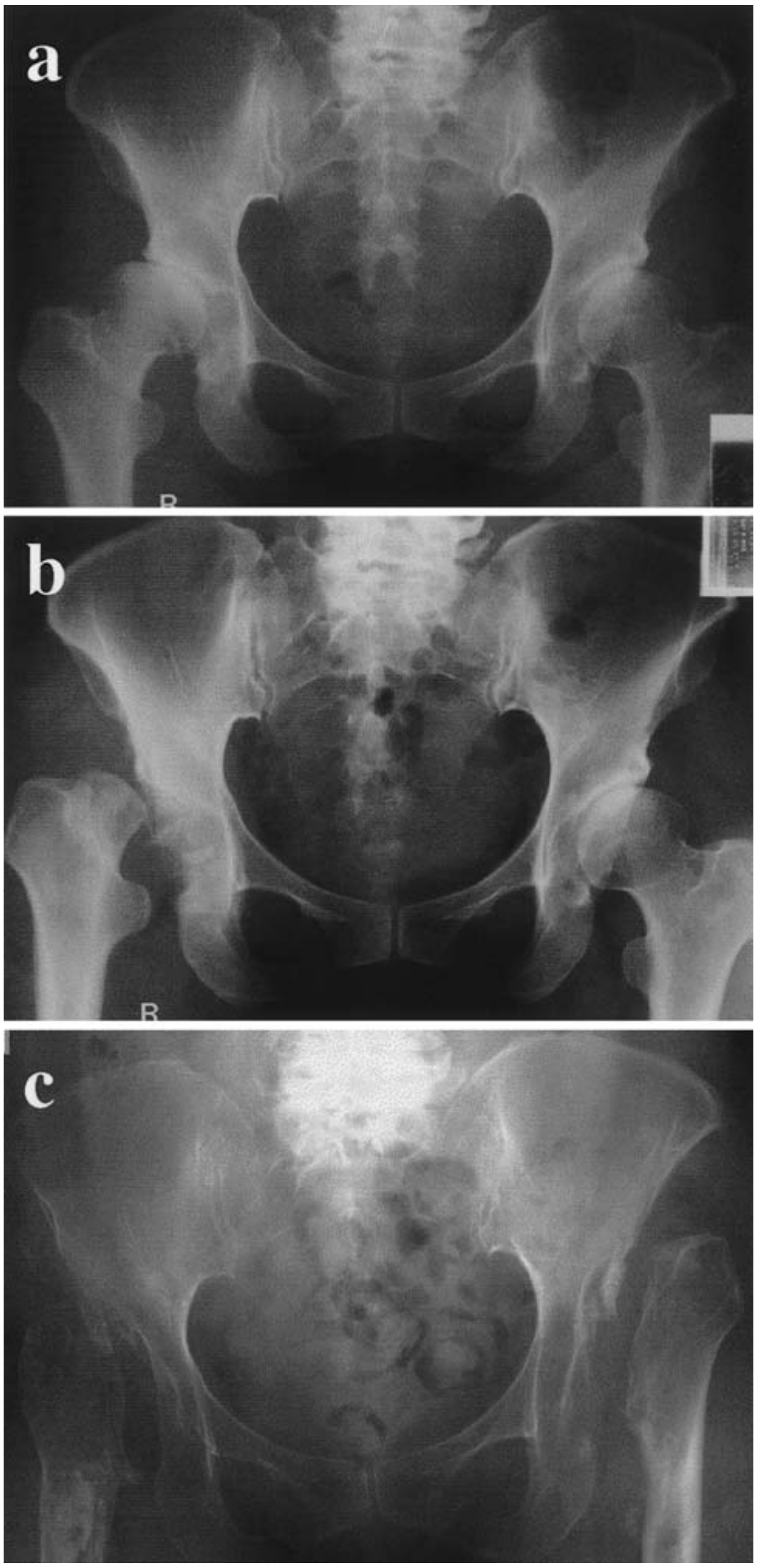

Fig. 1. Sequential radiograms of the hip joints of a 43-year-old woman with neuropathic arthropathy. **a** In April 1987 the acetubula were dysplastic with osteosclerotic changes in load-bearing areas. Linear fractures and fragmentation on the right hip joint were seen. **b** One month later, the right femoral neck was absorbed with hip dislocation. **c** Fifteen years later, upward migration of the femoral necks had increased, and the left femoral head was absorbed

and suggested a dumbbell tumor (Fig. 3). Magnetic resonance imaging (MRI) showed the tumor to be compressing the spinal cord. The tumor appeared as an area of low signal intensity in a T1-weighted image and as high signal intensity in a T2-weighted image (Fig. 4). Bone scintigraphy demonstrated increased uptake in the right hip joint but no remarkable uptake in the cervical spine.

Fig. 2. Radiogram of the cervical spine. Note the extensive, smooth erosion of the right C4–5 intervertebral foramen (*arrowhead*)

Fig. 3. Computed tomography scan at the fifth cervical vertebral level, demonstrating erosive changes of the C5 right vertebral body, transverse process, and lamina, as well as the dumbbell tumor

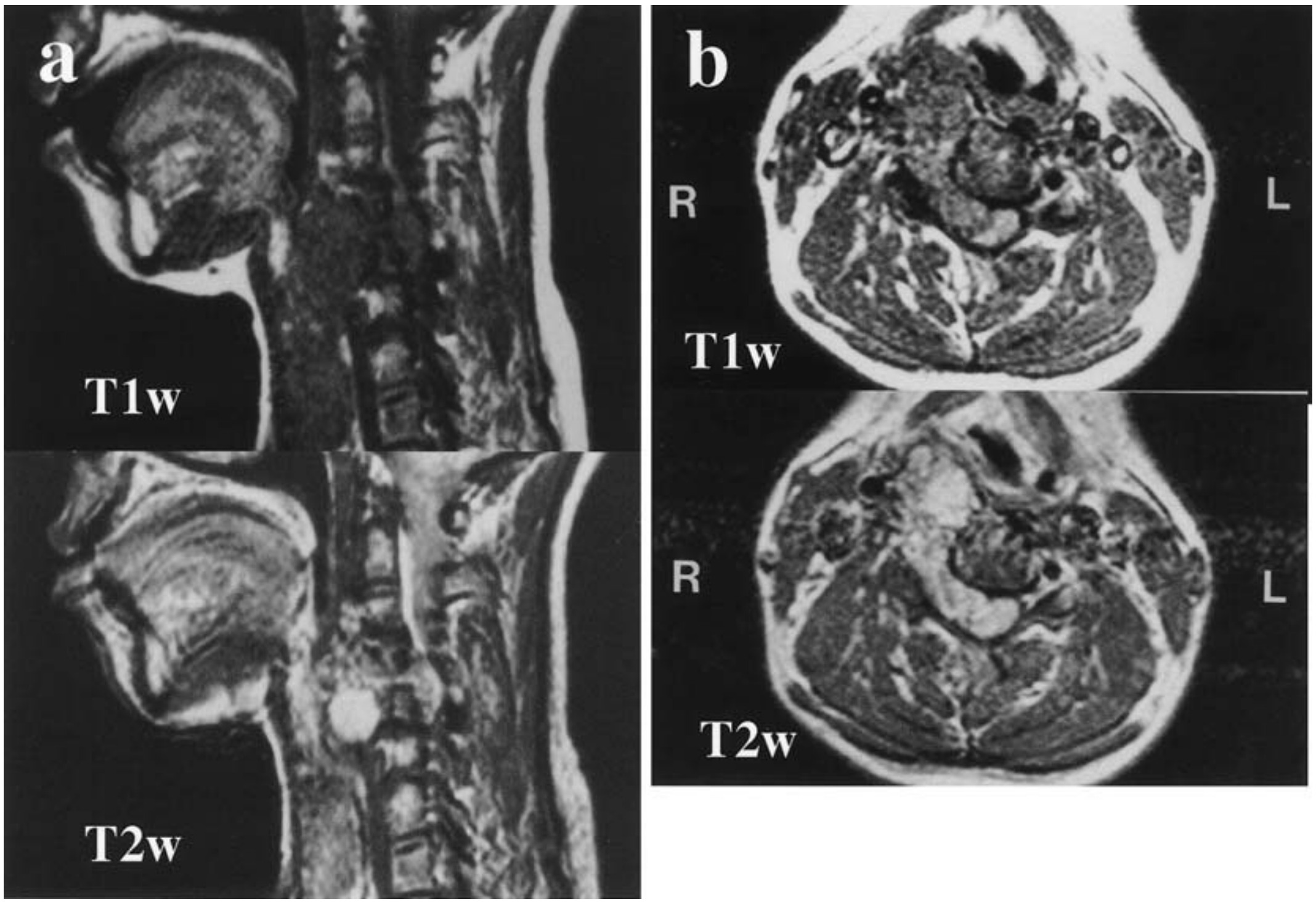

Fig. 4. Sagittal (**a**) and axial (**b**) magnetic resonance imaging (MRI) scans of the cervical spine. T1-weighted image (*T1w*) shows the tumor as areas of low signal intensity and T2-weighted images (*T2w*) as areas of high signal intensity. These scans showed the tumor to be compressing the spinal cord. *R*, right; *L*, left

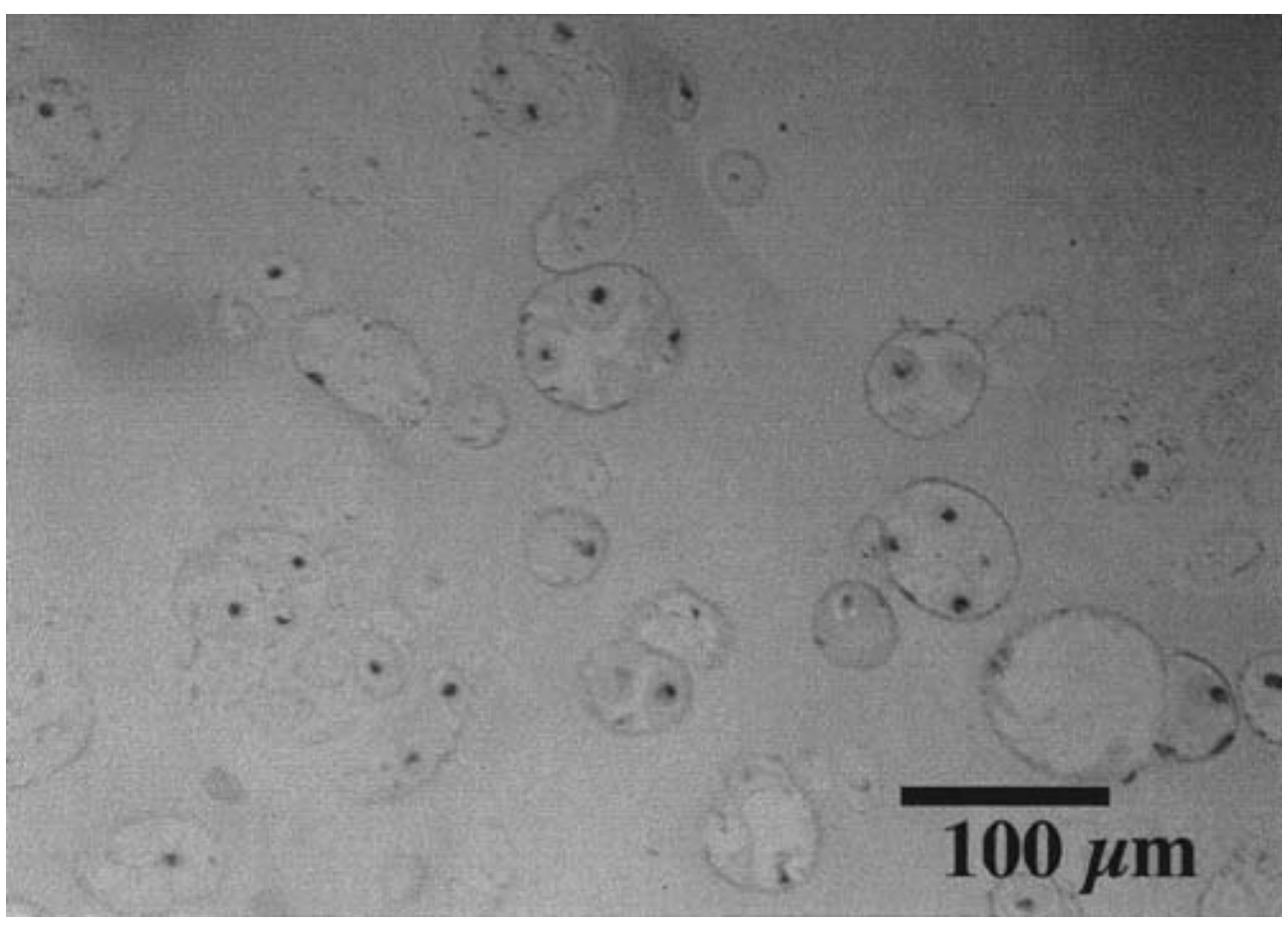

Fig. 5. Chondrosarcoma grade 1 shows slight nuclear enlargement focally and scattered binuclear cells, with slight variations in cell size and shape. Lacunae contain a clear space around the gray cytoplasmic mass of the cell bodies. H&E, *bar* 100 μm

Fig. 6. At 15 years of follow-up, note the complete disorganization and fragmentation of the left glenohumeral joint

On August 11, 1987, piecemeal dissection of the tumor was attempted from posterior and anterior approaches simultaneously. The tumor, a gray rubbery mass, existed in the right anterolateral extradural space and was severely compressing the dura mater. Careful examination confirmed that the tumor originated from the C4 vertebral body. Histological examination revealed a well-differentiated grade 1 chondrosarcoma (Fig. 5). A core biopsy of bone and joint fluid from the right hip joint cavity revealed no evidence of malignant cells or infection. Two months later, right femoral head replacement (FHR) was carried out with additional bone grafting of the iliac bone to the acetubulum. Unfortunately, this FHR failed, with gross loosening, in 1989.

The left femoral head destruction occurred in June 1988. A local recurrence of the cervical tumor had required a second surgical resection during 1988 as well. An anterior approach was used, and a vascularized fibular strut graft was implanted. In 1994, another recurrence led to spinal cord compression, resulting in urinary retention, constipation, and bilateral paresis of the lower extremities. This forced a third surgical intervention, a laminectomy from C1 to C3, to decompress the spinal cord.

The patient has remained alive with her disease. The last total skeletal radiographic examination in 2002 showed further joint destruction by neuropathic arthropathy in the left glenohumeral joint (Fig. 6) and the first metacarpophalangeal joints. At this point, the bilateral hip joints were completely destroyed (Fig. 1c).

Table 1. Causes of neuropathic arthropathy

Tabes dorsalis
Diabetes mellitus
Syringomyelia
Injury of the spinal cord and peripheral nerves
Congenital insensitivity to pain
Spinal dysraphism
Multiple sclerosis
Leprosy
Charcot-Marie-Tooth disease
Alcoholism
Amyloidosis
Pernicious anemia
Arachnoiditis
Paraplegia
Familial interstitial polyneuropathy
Intraarticular steroid injection
Familial dysautonomia
Hereditary sensory neuropathy
Congenital thalidomide syndrome
Myelomeningocele
Rheumatoid arthritis
Idiopathic

Discussion

Neuropathic arthropathy, or Charcot's joint, is an unusual form of chronic, progressive degenerative joint disease that affects one or more peripheral joints or the spine. It is caused by a disturbance of the normal sensory innervation of the joints. Many causes of neuropathic arthropathy have been described, including tabes dorsalis and diabetes mellitus (Table 1).[1] A diagnosis of neuropathic arthropathy is required for identification of an underlying neurological disorder. Our patient complained of disproportionately little pain with respect to the degree of destruction of the right hip joint. In her case, all of the above pathological conditions were ruled out by the clinical and laboratory tests performed in our hospital. It can be conjectured that compression of the spinal cord due to the cervical tumor led to loss of proprioceptive sensation. In fact, the symptoms of the patient were atypical for spinal cord compression at the C4–5 level. We speculated that the pathomechanism was associated with malcirculation of the microvascularization in the spinal cord around the tumor.

To our knowledge, widening of the intervertebral foramen secondary to a chondrosarcoma is rare, with only three cases having been reported previously.[2–4] The common causes of the dumbbell tumor are neurofibroma and meningioma.[5] Although chondrosarcoma is the second most common primary malignant tumor of the bone (osteosarcoma is most common), its occurrence in the spine is rare.[6,7] In general, the recommended treatment for a chondrosarcoma is radical excision of the tumor when feasible. However, surgical treatment of a cervical spine lesion is even more difficult because total excision is usually impossible. Intralesional excision or contaminated marginal excision usually leads to recurrence. Hirsh et al. suggested that repeat surgery for local recurrence can prolong survival.[8] The location of the tumor, as well as the histological grade, influences the prognosis of the patient with chondrosarcoma.[9] We believe that the cervical spine chondrosarcoma in our patient led to chronic cord compression of the sensory system and the subsequent development of neuropathic arthropathy.

References

1. Ellman MH. Neuropathic joint disease (Charcot joints). In: Koopman WJ, editor. Arthritis and allied conditions: a textbook of rheumatology. 14th ed. Philadelphia: Lippincott Williams & Wilkins; 2001. p. 1845–65.
2. Ohue S, Sasaki S, Kohno K, Nakagawa K, Kusunoki K, Todo H, et al. Primary spinal chondrosarcoma localized in the cervical spinal canal and intervertebral foramen. Neurol Med Chir (Tokyo) 1995;35:36–9.
3. Yünten N, Çalli C, Zileli M, Üstün EE, Sener RN. Chondrosarcoma cuasing cervical neural foramen widening. Eur Radiol 1997;7:1028–30.
4. Zibis AH, Markonis A, Karantanas AH. Unusual causes of spinal foraminal widening. Eur Radiol 2000;10:144–8.
5. Eden K. The dumb-bell tumours of the spine. Br J Surg 1941;28:549–70.
6. Camins MB, Duncan AW, Smith J, Marcove RC. Chondrosarcoma of the spine. Spine 1978;3:202–9.
7. Shives TC, McLeod RA, Unni KK, Schray MF. Chondrosarcoma of the spine. J Bone Joint Surg Am 1989;71:1158–65.
8. Hirsh LF, Thanki A, Spector HB. Primary spinal chondrosarcoma with eighteen-year follow-up: case report and literature review. Neurosurgery 1984;14:747–9.
9. Bergh P, Gunterberg B, Meis-Kindblom JM, Kindblom LG. Prognostic factors and outcome of pelvic, sacral, and spinal chondrosarcomas: a center-based study of 69 cases. Cancer 2001;91:1201–12.